

Partial Duplication of External Jugular Vein Forming a Venous Ring Around Supraclavicular Nerve: A Case Report

RAJAN KUMAR SINGLA, SANJU SINGLA, KANIKA SACHDEVA

ABSTRACT

External Jugular Vein (EJV) is an important superficial vein draining head & neck region. It usually lies singly on both sides of neck and drains to subclavian vein. Rarely it may be double on either side. In the present case, there was seen partial duplication of the right

EJV in the form of a venous ring enclosing supraclavicular nerve. The vein bifurcated 1 cm below the nerve point and the branches rejoined with each other to form a venous ring. The ontogenic basis and clinical implications of the entity are discussed.

Key Words: External Jugular vein, Supraclavicular Nerve, Venous Ring

INTRODUCTION

Deviation from the normal pattern in the vascular system is a common feature and it is far commoner in the veins than in the arteries. The subcutaneous veins of the body including the EJV (External Jugular vein), may vary considerably in morphology, relative size, disposition, anastomosis, tributaries, valves and termination.

The external jugular vein, one of the main superficial veins of the head and neck, drains blood mostly from the scalp and the face. It is formed by the union of the posterior division of the retromandibular vein with the posterior auricular vein. It begins at the level of the angle of the mandible or in the parotid gland and runs down the neck towards the middle of the clavicle. It crosses the sternocleidomastoid muscle obliquely and in the subclavian triangle perforates the deep fascia. It crosses the transverse cervical nerve and its upper half runs parallel to the great auricular nerve which ascends behind it. It varies in size, occasionally being double [1]. The clinical importance of this vein lies in the fact that it is used as a venous manometer and for catheterization [2]. It is important medicolegally [3] and for surgeons who do head and neck surgery as they have to avoid it while executing a submandibular incision to expose the mandible [4]. It is also a preferred option in the head and neck free tissue transfer as the recipient vein [5].

MATERIAL AND METHODS

In the routine departmental dissections for undergraduate students, a rare anomaly of EJV was encountered in a 50 years old male cadaver, on the right side. The vein was meticulously dissected by the authors. The area was cleaned and photographed.

OBSERVATIONS

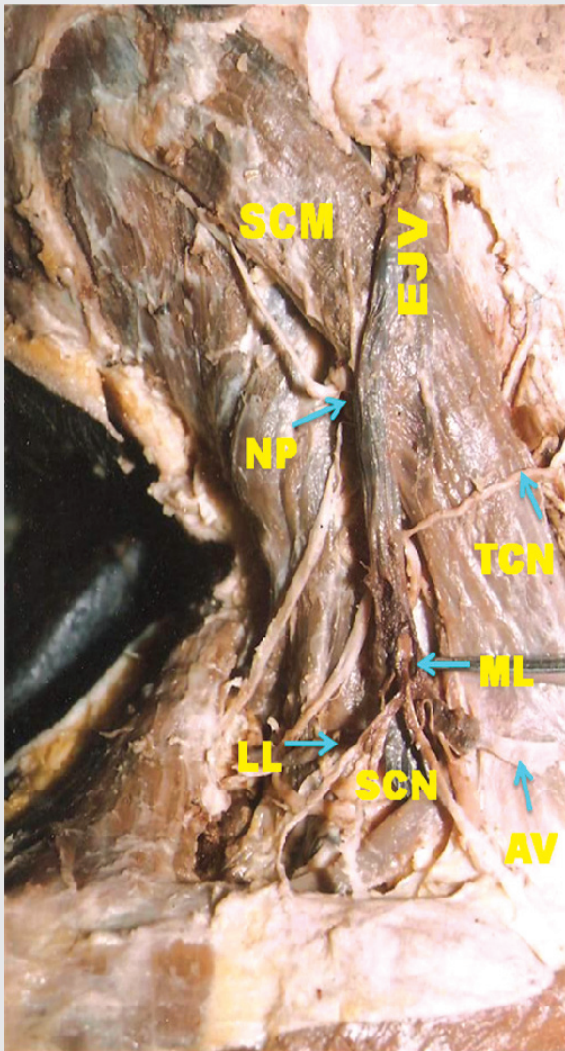
The external jugular vein on the right side was formed in the parotid gland and emerged from its apex. Thereafter, it crossed the SCM muscle obliquely, with the greater auricular nerve running parallel to and behind it. The vein descended to the nerve point where four nerves (greater auricular, lesser occipital, transverse cervical and supraclavicular) emerged and spread up for their respective destinations. One cm below this, the vein divided into two branches, one smaller medial and a larger lateral

with the supraclavicular nerve passing in between the two. After another one cm, these two branches joined with each other to reform the EJV. Thus, a venous ring was formed which encircled the supraclavicular nerve. The anterior smaller segment of the ring also received a transverse jugular vein from the opposite sided EJV, which was normal in its course and termination. The supraclavicular nerve after passing through this venous ring of the EJV, divided into its three terminal branches i.e. medial, intermediate and lateral ones. (Table/Fig-1)

DISCUSSION

The superficial veins of the head and neck, especially the external jugular vein are increasingly being utilized for cannulation to conduct diagnostic procedures or intravenous therapies [4-6]. The inspection, auscultation and doppler sonographic examination of the jugular veins may give a clue for the diagnosis of cardiac diseases [2]. Ultrasound guided venipuncture is a viable possibility in cases of variations in the pattern of the superficial veins. So, their knowledge is important for surgeons who do reconstructive surgery [6], radiologists who do catheterization and clinicians in general [7]. The veins of the head and neck, particularly the EJV, is reported to depict numerous variations which affect its size, form, tributaries, drainage, course and termination [3,8,9,10,11]. However a venous ring formed around supraclavicular nerve could not be traced. Out of the four cases of anomalous facial vein & EJV reported by Choudhry et al [9] (1997), in one the EJV split into two channels on the external surface of the SCM muscle and reunited at its junction with facial vein. However, this ring formed did not give passage to the supraclavicular nerve as was found in the present case.

Another closely related entity, the duplication of EJV or the double EJV has been reported in 5.3% of dissections by Pikkieft [11], 1937. Other workers like Hollinshed [12] (1982) and Williams [1] et al (1998) have made a mention of this entity without narrating the incidence. However in their cases, the whole EJV was duplicated, while in the present case, only a small segment of it was duplicated in the form of a venous ring, which trapped the supraclavicular nerve in between.



[Table/Fig-1]: Showing duplication of external jugular vein forming a ring around Supraclavicular Vein

ONTOGENY

The development of the veins of the scalp, face and neck has not been clearly understood nor has been the cause of their variations [9]. The principle cephalic vein which is formed early in the embryonic life disappears, thus necessitating the formation of venous spaces which connect and form channels, thus leading to the origin of the facial and pharyngeal veins [13]. Their enlargement at some places and diminution at others result in a retiform arrangement. Some primitive channels evolve and enlarge to form the definitive ones [14]. Two main venous channels have been observed in this region in an embryo with a length of 10 mm i.e. the primitive maxillary vein and the ventral pharyngeal vein which drain the rapidly growing mandibular and the hyoid arches into the common cardinal vein [9].

Simultaneously, a small cranial tributary of the primitive cephalic vein in the arm at stage 6, has grown larger in the differentiating tissues of the neck and joins the jugulocephalic vein which is craniodorsal to the cartilaginous clavicle, which is now surrounded by a venous ring. The caudoclavicular part of this ring is a new anastomosis whereby the definitive cephalic vein overcomes its jugulocephalic detour and becomes directly continuous with the subclavian vein now definitive. The old proximal end of the primitive cephalic vein, which is the craniodorsal part of the clavicular venous ring may be recognised as a trunk of the adult EJV. The part of

the venous ring which is ventral and superficial to the clavicle i.e. the jugulocephalic segment of the primitive cephalic vein often dwindles at stage 6 and is usually lost [15].

Further, the developing EJV makes two connections, anterior and posterior with the facial vein and with the retromandibular vein respectively. Under normal circumstances, the anterior connection disappears so that the facial vein continues to drain via the common facial vein into the precardial vein (adult IJV), whereas the posterior connection persists, so that the retromandibular vein drains into the EJV.

In the present case, it seems that in the early embryonic life, the principle cephalic vein has disappeared and different venous spaces have been formed normally. However, there occurred failure on the part of some of these spaces to retrogress, which usually should have disappeared so that a double EJV is left in a small segment which has also entrapped the supraclavicular nerve.

CLINICAL IMPORTANCE

The external jugular venous ring which encircles the supraclavicular nerve is important in cases of increased jugular venous pressure as it may compress the supraclavicular nerve, thus causing pain or hyperaesthesia in the area of its distribution. Moreover, an attempt to cannulate the vein in this region may injure the supraclavicular nerves. So, one must be familiar with such a variation.

ABBREVIATIONS

AV	: Anastomosing Vein
EJV	: External Jugular Vein
LL	: Lateral Limb
ML	: Medial Limb
NP	: Nerve Point
SCM	: Sternocleidomastoid Muscle
SCN	: Supraclavicular Nerve
TCN	: Transverse Cutaneous Nerve

REFERENCES

- [1] Standing S and Berkovitz B KB. Neck. In: *Standing S. Gray's anatomy: The anatomical basis of clinical practice*. 39th ed. Edinburgh, London: Elsevier Churchill living stone; 2005: 1428-31.
- [2] Baumgartner I, Bollinger A. Diagnostic importance of the jugular veins. *Vasa* 1991; 20(1): 3-9.
- [3] Salmeri KR, Bellah JR, Ackerman N, Homer B. Unilateral congenital aneurysm of the jugular, linguofacial and the maxillary veins in a dog. *J Am Vet Asso* 1991; 198(4): 651-4.
- [4] Patnaik WVG, Singla RK, Bala S. Surgical Incisions, their Anatomical basis. Part (1) Head and Neck. *J Anat Soc Ind* 2000; 49(1): 69-77.
- [5] Comert E, Comert A. The external jugular vein duplication. *J Craniofacial Surg* 2009 Nov; 20(6): 2173-4.
- [6] Gupta V, Tuli A, Choudhry R, Agarwal S, Mangal A. The facial vein draining into the external jugular vein in humans: its variation, phylogenetic retention and clinical relevance. *Surg Radiol Anat* 2003 Apr; 25(1): 36-41.
- [7] Nayak BS. Surgically important variations of the jugular veins. *Clin Anat* 2006 Sep; 19(6): 544-6.
- [8] Yadav S, Ghosh SK, Anand C. Variations of the superficial veins of the head and neck. *J Anat Soc Ind* 2000; 49(1): 61-62.
- [9] Choudhry R, Tuli A, Choudhry S. Facial vein terminating in EJV – An embryonic interpretation. *Surg Radiol Anat* 1997; 19: 73-77.
- [10] Dhillon MR, Leong YP. Jugular venous aneurysm- A rare case of neck swelling. *Singapore Medical Journal* 1991; 32(2): 177-8.
- [11] Pikkieft E. Subcutaneous veins of the neck. *Journal of Anatomy* 1937; 72: 119.
- [12] Hollinshed WH: *Anatomy for surgeons Vol 1*. The Head and Neck. 3rd edn. Harper and Row; 1982: 467.
- [13] Frazer JE. A manual of embryology. In: *The development of human body*. London: Bailliere Tindal and co. London; 1931: 321.

[14] Romanes GJ. Cunningham's *Textbook of Anatomy*. 12th ed. London: Oxford University Press; 1981: 62.

[15] Padgett DH. Contributions to embryology. In: *Development of the cranial venous system in man, from the view point of comparative anatomy*. Cornell University of Washington, Baltimore; 1957: 106-110.

AUTHOR(S):

1. Dr. Rajan Kumar Singla
2. Dr. Sanju Singla
3. Dr. Kanika Sachdeva

PARTICULARS OF CONTRIBUTORS:

1. Associate Professor
Department of Anatomy,
Government Medical College
Amritsar-143001, Punjab, India.
2. Professor, Department of Oral & Maxillofacial Surgery
Dasmesh Institute of Research & Dental Sciences
Faridkot, Punjab, India.
3. Corresponding Author.

NAME, ADDRESS, TELEPHONE, E-MAIL ID OF THE CORRESPONDING AUTHOR:

Dr. Kanika Sachdeva, Assistant Professor,
Department of Anatomy, Chintpurni Medical College,
Pathankot, Punjab, India.
E-mail: kanikadr.sarang@yahoo.com.

DECLARATION ON COMPETING INTERESTS:

No competing Interests.

Date of Submission: **Apr 07, 2011**
Date of Peer Review: **May 04, 2011**
Date of Acceptance: **May 04, 2011**
Date of Publishing: **Aug 08, 2011**